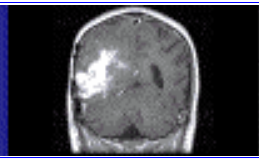


share expertise

click 



Improving the Accuracy of Diagnostic Breast Ultrasound

Michael P. Andre, Ph.D., UCSD Medical School ([learn more about the author - click here](#))

Michael Galperin, Ph.D., Almen Laboratories, Inc ([learn more about the author - click here](#))

The Status of Clinical Breast Ultrasound

X-ray mammography is the established screening tool for breast cancer. It is sensitive to early indications of disease but in many cases the findings are not sufficiently specific so subsequent diagnostic work up is required. Ultrasound is the primary adjunctive tool to mammography for diagnosis of suspicious findings. However, until recently, ultrasound has been mainly used to distinguish cystic from solid breast masses and to guide needle biopsies. A number of studies in Europe, Asia and the U.S. indicate that high-quality ultrasound can aid radiologists to differentiate with a greater degree of confidence many benign from malignant or suspicious lesions detected by mammography. Results suggest that ultrasound in such expert hands could help reduce the number of unnecessary biopsies by at least 40%. Approximately 700,000 women undergo breast biopsies (surgical or needle) in the U.S. each year. In the United States, approximately 75-80% of tumors biopsied are benign and 20-25% are malignant. Surgical biopsies--the most common--cost between \$2,500 and \$5,000 while needle biopsies cost from \$750 to \$1,000. Reduction of breast biopsies by 40% would result in cost savings of as much as \$1 billion per year in the U.S. alone. It is also important to consider that patients experience emotional stress and physical effects when undergoing biopsy procedures. Internal scarring from biopsies is problematic since it may complicate interpretation of future mammograms. A high priority for researchers is to find ways to reduce the number of biopsies performed on benign masses.

Almen Laboratories' Technology to Reduce Unnecessary Biopsies

Almen Laboratories, Inc. is developing imaging technology for application in ultrasound that promises to reduce the number of breast biopsies. This sophisticated software tool is based on technology originally developed for satellite imagery and reconnaissance applications that necessitate an advanced accuracy of processing. The goal of this ultrasound application is to automatically classify benign lesions with a sufficiently high degree of confidence such that unnecessary biopsies may be avoided. The developed software system will be incorporated into an ultrasound Picture Archiving and Computer System workstation in a way that image scoring and classification will be available real-time and "on-line" to radiologists during interpretation and reporting. The approach is to provide image analysis tools that aid the radiologist to apply the well-defined system

for “scoring” from 1 to 5 the Level of Suspicion (LOS) of a breast mass. Almen Labs’ computer system measures image parameters that are known to precisely describe the ultrasound appearance of a suspicious breast lesion. The underlying premise is that the accuracy of diagnostic breast ultrasound can be significantly improved by measuring and analyzing the ultrasound attributes of a suspicious mass. Furthermore, with this software tool breast masses will be automatically scored for Level of Suspicion for cancer by applying computer image analysis algorithms following the criteria established in the medical ultrasound world for scoring LOS (Table 1). Lesions of lower suspicion level (high level of relative similarity to other benign lesions such as complex cystic masses) may then be accurately classified with a high degree of correctness without the need for biopsy.

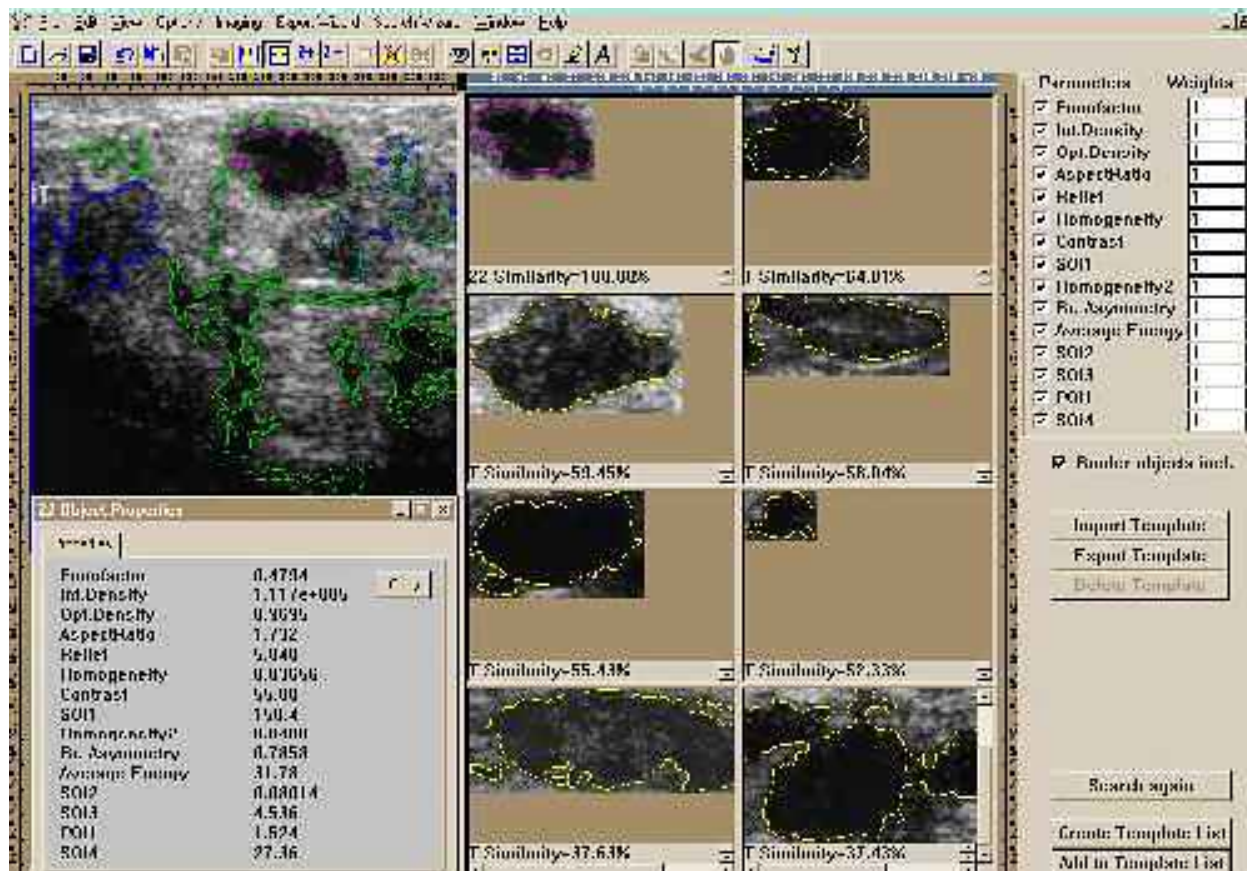
Table 1. Established Scoring Criteria.

| Image Criteria Associated (with Benign Lesions) | Image Criteria Associated (with Malignant Lesions) |
|--|---|
| Spherical/ovoid/lobulated shape | Irregular shape |
| Linear margin | Poorly defined margin |
| Homogeneous texture | Central shadowing |
| Isoechoic/anechoic | Distorted architecture |
| Edge shadow | Calcifications |
| Parallel to the skin | Skin thickening |
| Distal enhancement | |
| Dilated duct/mobile | |

Almen Labs’ software calculates features of the mass and stores the image or templates extracted from the image in a database for future retrieval and comparison based on its information content. One long-term goal of this advanced research is to use similar computer classification parameters to create a novel database to store, retrieve and compare images based on the image content¹. This database may serve as a valuable teaching resource to assist radiologists in learning the complexities of breast ultrasound image interpretation. It may also reduce variability among radiologists. In the routine clinical setting, the software system would function as a “second reader” resource to assist diagnosis of suspicious unknowns by precisely referencing to already known findings in other cases. Finally, it is anticipated that this approach to image storage and retrieval by information content would serve as a unique model to design highly efficient computer networks for radiology departments, including a professional ASP Internet deployment.

Scientists at Almen Labs are also working to extend this technology to other important applications of diagnostic ultrasound such as assessment of carotid artery stenosis and management of cancer of the ovaries, prostate, liver, etc., and to medical problems involving other imaging modalities such as computed tomography (CT) and magnetic resonance imaging (MRI). These developments may also be used to guide and monitor tumor ablation therapy as well as to monitor tumor response to other therapies.

An example of the software analysis is shown in the computer screen snapshot below.



(click on the image for enlarged viewing)

In this case, a complex cyst (benign) is evaluated for its relative similarity to other images in the template database. The mass in question is displayed in the upper left portion of the screen and is highlighted by the cyan contour. Note this mass has a dark, relatively echo-free central region consistent with a fluid-filled cyst but it has irregular indistinct margins more consistent with a solid mass that might have a higher suspicion for cancer. The software automatically and accurately locates the boundary of this suspicious mass and highlights it in cyan. Multiple measurements are then made of the shape, relative location, relief and texture of the mass and it is compared to a imaging database of previously analyzed patients. The cases most “similar” to this suspicious mass are automatically retrieved and displayed in the thumbnail images on the right. A “relative similarity” index number is calculated and the images are listed in rank order of this value (yellow contours in the left half of the screenshot). In this case, all of the “similar” masses were proven to be benign. Then radiologist may more confidently decide that no further work up may be necessary. Using this method, a radiologist may readily compare the features of an unknown mass to his previous clinical experience, or that of a standardized collection of cases for which the surgical or biopsy results are known.

The Opportunity

The American College of Radiology is currently engaged in developing a detailed guide for implementing the LOS system similar to the Breast Imaging Reporting And Data System (BIRADS) for x-ray mammography and the ACR is detailing a program to accredit the clinical practice of breast ultrasound. The American Institute of Ultrasound in Medicine has already launched a program in 1998 to accredit the breast ultrasound practices of radiologists and sonographers. These steps by professional organizations are designed to improve uniformity of practice and quality of care. Acceptance and utilization of this Level of Suspicion Score is increasing but it is proving difficult to teach the method and many radiologists feel uncomfortable with the number of benign and malignant masses that overlap in appearance. Furthermore, the scoring of breast ultrasound by different radiologists was found to be highly variable in many studies. Image quality of breast ultrasound may also be highly dependent on instrument settings and the skill and training of the sonographer or physician operator. Masses that are definitely malignant may show benign features in some projections, the converse for benign masses. Despite the increasing number of positive reports touting the ability of sonography to distinguish benign from malignant solid nodules, it is still likely that a majority of radiologists in the U.S. recommend that sonography be used only to determine whether a lesion is cystic or solid and for needle guidance. If a lesion is solid or indeterminate, biopsy is frequently recommended. Furthermore, even with combined information from mammography and ultrasound it is true that each radiologist may apply a different decision threshold to biopsy a suspicious mass. With the aid of Almen Laboratories' computer analysis, it is hoped these differences can be minimized and the number of biopsies of benign masses can be significantly reduced.



Almen Laboratories, Inc. Copyright © 2000 All rights Reserved. Published in the United States of America.

The article may be reproduced or disseminated only as a whole and with explicit references to the authors and Almen Laboratories, Inc.

¹ Patent Pending.